

Accuracy and efficacy of intra-articular hip injections under ultrasound guidance versus landmark and fluoroscopy guided injections: A systematic review

Alia Hemeida¹, Donald Kasitinon¹, Lindsey Kim¹, Reed Williams², Levent Özçakar³, Nitin B. Jain⁴

¹Department of Physical Medicine and Rehabilitation, The University of Texas Southwestern, Dallas, TX, USA

²Summit Orthopedics, Twin Cities, MN, USA

³Department of Physical Medicine and Rehabilitation, Hacettepe University Faculty of Medicine, Türkiye

⁴Department of Physical Medicine and Rehabilitation, University of Michigan, Ann Arbor, MI, USA

Abstract

Objectives: In this systematic review, we discuss the literature regarding the accuracy and efficacy of ultrasound (US)-, fluoroscopy (FL)-, and landmark (LM)-guided intra-articular hip injections.

Materials and methods: A systematic review was performed following the Cochrane process from April 2023 to August 2023 utilizing PubMed, Embase, Web of Science, and Scopus databases. Branched logic was used to include any articles that were published prior to April 2023 containing the key terms “hip” AND “ultrasound” AND “injections”. Two authors screened studies for eligibility, and any disagreements were resolved through discussion with a third reviewer. Risk-of-bias assessments were performed.

Results: A total of five studies were included in the review. Individual studies demonstrated accuracy amounted to 100% (17/17) versus 85.4% (53/62) versus 70% (52/74) for US-, FL- and LM-guided intra-articular injections/arthrocentesis, respectively. All studies, except for one, addressing either the injection accuracy or improvement in pain showed improved outcomes in the US-guided injection/aspiration groups.

Conclusion: This systematic review provides preliminary evidence for slightly better accuracy with US-guided intra-articular hip injections/arthrocentesis versus FL- or LM-guided intra-articular hip injections/aspirations. It contributes to the current literature by evaluating multiple measurable outcomes, including procedural accuracy, changes in pain scores, patient-reported procedural discomfort, and improvements in range of motion.

Keywords: Fluoroscopy, hip, injection accuracy, intra-articular, pain outcomes, ultrasound.

Intra-articular hip pain is common in both athletes and aging adults.^[1] In athletes, intra-articular hip pain is usually due to femoroacetabular impingement, labral tears, or

chondral defects. Meanwhile, in older adults, osteoarthritis is most common.^[1] Conservative treatment measures which can be considered for these patients include medication, physiotherapy,

Submitted: January 24, 2026

Accepted: March 28, 2026

Published: May 15, 2026

Correspondence: Nitin B. Jain, MD, MSPH. Department of Physical Medicine and Rehabilitation, University of Michigan, Ann Arbor, MI, 48108 USA.

E-mail: jainnb@med.umich.edu

Doi: <https://doi.org/10.5606/archisprm.2026.10>

Citation:

Hemeida A, Kasitinon D, Kim L, Williams R, Özçakar L, Jain NB. Accuracy and efficacy of intra-articular hip injections under ultrasound guidance versus landmark and fluoroscopy guided injections: A systematic review. Arch ISPRM 2026;1(2):106-113. <https://doi.org/10.5606/archisprm.2026.10>.

© 2026 The Author(s). This is an open access article distributed under the terms of the Creative Commons Attribution-NonCommercial-NoDerivatives 4.0 International License (CC BY-NC-ND 4.0), which permits non-commercial use, distribution, and reproduction in any medium, provided the original work is properly cited and is not modified. <https://creativecommons.org/licenses/by-nc-nd/4.0/>

and injections.^[2] Intra-articular hip injections can be done via anatomic landmark (LM), fluoroscopy (FL), or ultrasound (US) guidance. Previous studies have evaluated the accuracy of US-guided injections compared to anatomic LM guidance.^[3] However, there is no study comparing FL, US, and anatomic LM guidance on the accuracy and efficacy of pain improvement in intra-articular hip injection.

In this review, we discuss the accuracy and efficacy of US-, LM-, and FL-guided intra-articular hip injections to help synthesize the existing literature on evidence for accuracy and efficacy of these three injection methods.

MATERIALS AND METHODS

Search strategy

A systematic review was done following the Preferred Reporting Items for Systematic Reviews and Meta-Analyses (PRISMA) guidelines and the Cochrane process from April 2023 to August 2023. Review guidelines were established prior to performing the literature review. This was performed using multiple databases (PubMed, Embase, Web of Science, and Scopus) for English published articles prior to April 2023. Branched logic was used to include articles containing terms regarding the hip (“hip” OR “hip joint” OR “hip pathology” OR “femoroacetabular impingement” OR “labral tear” OR “acetabulum” OR “hip injuries” OR “hip osteoarthritis”) AND ultrasound (“ultrasonography” OR “interventional ultrasonography” OR “ultrasound” OR “ultrasound-guided”) AND injections (“injections” OR “intra-articular injections” OR “ultrasound-guided injection” OR “hip injection” OR “saline solution” OR “placebo” OR local anesthetics” OR “hyaluronic acid” OR “orthobiologics” OR “platelet-rich plasma” OR “mesenchymal stem cells” OR “adipose tissue” OR “MEAT” OR “botulinum toxins” OR “palpation” OR “anatomic landmarks” OR “physical therapy modalities” OR “fluoroscopic guidance”. Two authors screened the studies for eligibility, and any disagreement was resolved through discussion with a third reviewer.

Outcome measures

The main outcome for this systematic review was to evaluate the accuracy of each intervention arm. Secondary outcomes were to evaluate for

efficacy of each treatment arm in relieving pain. The efficacy of each treatment was evaluated as a secondary measure, since pain relief as the measure of efficacy of the injection was not standardized across every study included. Due to the limited number of studies that evaluated two different injection modalities, a decision was made to prioritize the evaluation of injection accuracy. Some studies measured accuracy by needle placement or by location of contrast as seen on imaging or on cadaver dissection.

Data abstraction

Data abstraction was completed by a standardized approach for each study. In the data abstraction, the following fields were included when appropriate: first author, study objective, study design, country location of the study, age in terms of years of the participants, eligibility criteria outlined by the study, number of cases and controls, results, and conclusions of the study. Conclusions of these studies could include accuracy of the injection, convenience of the intervention, pain improvement, injection related pain, change in range of motion, or presence of extravasation of the injection dye.

Assessment of study quality

The Newcastle-Ottawa Quality Assessment Scale (NOS) and the Revised Cochrane Risk-of-Bias Tool for Randomized Trials (RoB 2) were utilized to assess the studies included in the systematic review by one reviewer.^[4] The quality of observational studies was assessed. The NOS provided a numerical score evaluating a study based on three domains: selection bias, comparability for assessment of confounding, and outcome/exposure. The RoB 2 evaluated the quality of randomized trials.^[4] The RoB 2 evaluates the given exposure risk and determines whether a study is at risk of “low”, “some concerns”, or “high risk”.

RESULTS

Overview

Initially, a total of 7,289 articles were identified to include the search terms: 3,135 articles from PubMed, 2,220 articles from Embase, 1,297 articles from Web of Science, 634 articles from Scopus, and three systematic review bibliographies. There were

1,482 duplicate records that were removed prior to screening. Over 5,807 articles were screened across all databases. A total of 5,763 articles were excluded based on their title and abstract. A total of 44 articles underwent a full text review for eligibility. Out of those articles that had a full text review, 39 articles were excluded as they had the wrong intervention, wrong study design (such as case report or case series or open letter to the editor), incomplete data, or did not include a comparison group. Five studies were included for final review after meeting the established criteria (Figure 1, Table 1). However, the review of outcomes such as accuracy, improvement in pain scores, comparison of procedural pain experience, and improvement in range of motion provided preliminary evidence which favored US-guided intra-articular hip injections/arthrocentesis for injection accuracy compared to FL- or anatomic LM-guided intra-articular hip injections/aspirations.

Risk of bias assessment

Out of the five studies, four were assessed using the NOS and one study was assessed using the RoB 2 (Tables 2a, b).

Ultrasound vs. Landmark Guidance

Of the five final articles for review, Berona et al.^[5] evaluated the efficacy of LM- versus US-guided intra-articular hip arthrocentesis. There were 17 cadaver specimens in which residents from PGY-1 to PGY-4 performed both US- and LM-guided intra-articular arthrocentesis. The rate of success for US-guided hip arthrocentesis and LM-guided hip arthrocentesis was 100% (17/17) and 82% (14/17), respectively in diagnosing and aspirating the joint fluid. There was not a statistically significant difference between anatomic LM- and US-guided intra-articular hip arthrocentesis success ($p = 0.08$). The NOS for this article developed a composite score of 5. Review of the literature revealed no prior live human study comparing anatomic LM guidance versus US guidance in the diagnosis and arthrocentesis of a hip joint effusion.

Ultrasound vs. Fluoroscopy Guidance

There were three articles that met eligibility criteria that focused on comparing US- and FL-guided intra-articular hip injections.^[6-8]

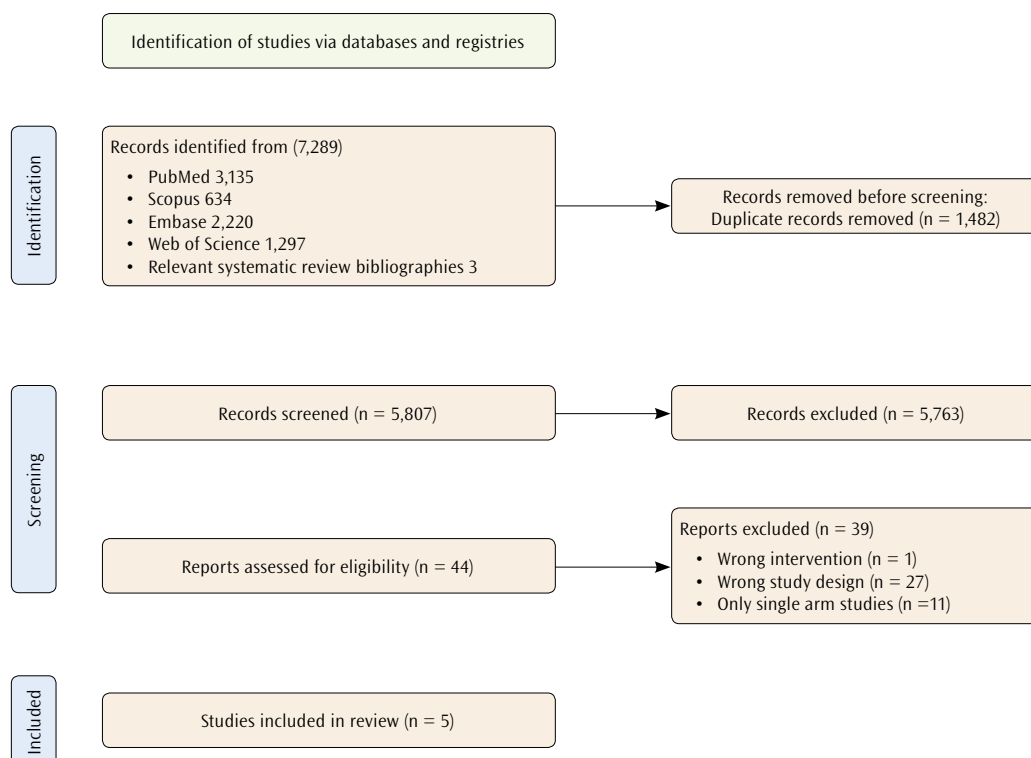


Figure 1. Article selection for systematic review.

Table 1. Article summary

Study	Objective	Design	Country	Age in years (range)	Eligibility Criteria	Number of cases and controls	Results	Conclusions
Berona et al. ^[6] 2017	To evaluate emergency medicine resident performed ultrasound (US) for diagnosis of effusions and compare the success of landmark (LM)-guided approach to US-guided technique for hip arthrocentesis.	Non-blind prospective study	USA	PGY1 to PGY4 Did not identify characteristics of the cadaver.	PGY1 to PGY4 residents who completed both the didactics and the cadaver practicum on how to diagnose a joint effusion on US and to perform an arthrocentesis on the joint.	Total hip injections = 34 cases US-guided injection = 17 cases LM-guided injection = 17 cases	Residents were successful in 17/17 (100%) US arthrocentesis attempts and 14/17 (82%) LM attempts ($p = 0.08$). Residents required a median of one attempt (mean 1.5) with US and two (mean 2) with LM (mean time to arthrocentesis was 38 s (mean 78 s) using US compared to 112 s (mean 124 s) with LM ($p = 0.11$)).	EM residents were able to identify and complete a hip arthrocentesis with US guidance on cadaver models. There was no significant difference in the procedural success between LM and US guidance.
Byrd et al. ^[6] 2014	To evaluate needle positioning during blind/anatomically referenced hip joint injections for osteoarthritis.	Experimental clinical study	Türkiye	Not Identified	Patients with osteoarthritis and radiographic evidence of grade 1 or 3 according to Kellgren-Lawrence with symptomatic hip pain	Total hip injections = 57 Patient total = 16 Number of injections per patient = 3 Bilateral hip injections = 3 Unilateral hip injections = 13	Confirmation of contrast intra-articular joint space uptake in FL- vs. LM-guided injection = 76.3% vs. 50.9%. Statistical significance of difference: $z = 2.27$; $p = 0.02$; power = 0.98.	Landmark guided intra-articular hip injection was significantly less accurate for needle placement in intra-articular hip injection compared to fluoroscopy guidance.
Furtado et al. ^[7] 2013	To compare the short-term effectiveness of US- vs. FL-guided intra-articular in patients with refractory hip synovitis.	Single-blinded, prospective study	Brazil	FL, 62 ± 16.0 US, 49 ± 10.8	Patients with refractory synovitis pain for at least one month and patients between the ages of 18-65 years old. Excluded patients with uncontrolled hypertension, diabetes, damage to the skin at the site for injection, suspected infection, severe clotting disorder, or with a known allergy to contrast	Total hip injections = 23 Fluoroscopy = 12 Ultrasound = 11	Improvement in hip pain by Visual Analog Scale in FL vs. US = 7.8 vs. 7.6 $p = 0.75$ Change in hip joint flexion after FL- vs. US-guided injection = 39.0 vs. 10.0 degrees, $p = 0.07$	In the hip subgroup analysis, both ultrasound and fluoroscopy guidance were equally effective for intra-articular hip injection with steroid for patients with refractory synovitis.

Table 1. Continued

Study	Objective	Design	Country	Age in years (range)	Eligibility Criteria	Number of cases and con-trols	Results	Conclusions
Martinez-Martinez et al. ^[6] 2016	To prove the utility of this modality of US-guided injection in computed tomography and magnetic resonance arthrography compared to radioscopic guidance through the assessment of contrast extravasation by both modalities as the main parameter. In addition, the presence of air bubbles introduced within the joint was also assessed in both samples and whether the study showed enough intraarticular contrast for diagnosis.	Retrospective review	Spain	15 - 58 (average 39.4)	Patients who underwent both computed tomography and magnetic resonance arthrography of the hip between October 1 st , 2014, and October 1 st , 2015 were reviewed. Excluded patients with mild extravasation (extravasation in the trajectory of the needle).	Total number of cases = 58 Men = 3 Female = 27 FL, 26 US, 32	Extravasation of hip injection (moderate to severe) US vs. FL = 56.3% vs. 53.8%, $p = 0.79$ Extravasation making diagnostic unfit US vs. FL = 6.3% vs. 3.8%, $p = 0.41$ Intra-articular gas finding US vs. FL = 21.9% vs. 38.5%, $p = 0.17$ Odds ratio for the risk of extravasation is 1.16 times greater with US than FL	Ultrasound is as useful as fluoroscopy for injection material for CT and MR arthroscopy. Ultrasound has the benefit of no radiation exposure.

PGY, Postgraduate year; EM, Emergency medicine; FL, Fluoroscopy; CT, Computed tomography; MR, Magnetic resonance imaging.

One of these articles was a retrospective review, one a single-blind study, and one a prospective comparative study. In Byrd et al.'s study,^[6] the patients had significantly lower level of procedural pain experience with US-guided compared to FL-guided injections ($p < 0.01$) and 98% of patients preferred US-guided intra-articular hip injections over FL-guided ones. Pain was rated from 1 to 10 (1, no pain; 10, very painful). Furtado et al.^[7] demonstrated an improvement in pain relief using the Visual Analog Scale (VAS) with both US- vs. FL-guided hip injections ($p = 0.75$). Neither Byrd et al.^[6] and Furtado et al.^[7] confirmed that injection accuracy was achieved in their interventions. In Martínez-Martínez et al.'s study,^[8] there was no significant difference in the rate of extravasation or intra-articular gas finding between US- and FL-guided intra-articular hip injections ($p = 0.41$ and $p = 0.17$, respectively). The NOS composite scores for Byrd et al.^[6] and Martínez-Martínez et al.^[8] were 4 and 5, respectively. The RoB 2 for Furtado et al.^[7] was noted to be of "some concern".

Fluoroscopy vs. Landmark Guidance

Of the five articles that met eligibility criteria, there was one article that compared the efficacy of FL- and LM-guided intra-articular hip injections.^[9] It was an experimental clinical study and evaluated accuracy of the injection by the confirmation of contrast uptake into the joint space. Diraçoğlu et al.^[9] reported that the accuracy of intra-articular hip injections was significantly better with FL guidance than LM guidance (76.3% vs. 50.9%, $p = 0.02$). The NOS composite score was 5.

DISCUSSION

In this systematic review, we evaluated the literature offering a comparison between the different image-guided modalities for intra-articular hip injections. Of note, this systematic review is limited by small studies and low quality of the included studies. Nevertheless, it provides preliminary evidence for slightly better accuracy of needle placement with US-guided intra-articular hip injections/arthrocentesis versus FL- or anatomic LM-guided intra-articular hip

Table 2a. Quality assessment using the Newcastle-Ottawa Quality Assessment scale of included studies

	Selection				Comparability	Outcome/exposure			Total score
Berona et al., ^[5] 2017	0	0	1	0	2	1	1	0	5
Byrd et al., ^[6] 2014	0	0	0	1	1	0	1	1	4
Diracoglu et al., ^[9] 2009	0	0	1	1	0	1	1	1	5
Martinez-Martinez et al., ^[8] 2016	0	0	1	1	0	1	1	1	5

Table 2b. Quality Assessment using the Revised Cochrane Risk-of-Bias Tool for Randomized Trials

Articles	Domain 1	Domain 2 ¹	Domain 2 ²	Domain 3	Domain 4	Domain 5	Assessment
Furtado et al. ^[7] 2013	Some concerns	Some concerns	Low risk	Low risk	Some concerns	Low risk	Some concerns

¹, effect of assignment to intervention; ², effect of adhering to intervention.

injections/aspirations. Both FL- and US-guided intra-articular hip injections provided significant pain relief. There is some evidence that procedural pain experienced by the patient decreases during an intra-articular hip injection with US-guidance compared to FL-guidance. Due to the low number of studies that evaluated these outcomes, further research is needed to make a strong conclusion on the superiority of US-compared to FL-guidance. Compared to anatomic LM-guided intra-articular hip injections, both US- and FL-guidance were found to be superior across the individual studies. In comparing success for injection/aspiration for the hip, cumulative accuracies amounted to 100% (17/17) vs. 85.4% (53/62) vs. 70% (52/74) for US-, FL-, and LM-guided hip injections/arthrocentesis, respectively.^[6-10] Accuracy was measured across the studies by either contrast within the joint, amount of extravasation into the surrounding muscle, or success in aspiration of fluid from the intra-articular hip joint. For inexperienced clinicians, there is a significant benefit to using image guidance for the hip due to the neurovascular structures within the area, injector comfortability, and accuracy of the needle placement.^[5,11,12] Efficacy as a measure of pain relief at Week 4 during follow-up was equivocal between FL- and US-guidance.^[6] However, patients reported that US-guidance was significantly more convenient and had less procedural pain compared to FL-guidance for intra-articular hip injection.^[7] Although it is too early to make a formal recommendation between FL- and US-guidance for intra-articular

hip injections, physicians may consider patient comfort and convenience when choosing an imaging modality.

Due to the rise of orthobiologics and the associated high cost for these interventions, there is an additional growing desire by both patients and providers to ensure accurate placement into the joint space. Providers can select from US, computed tomography, FL, and magnetic resonance imaging for safe and accurate intra-articular hip injections.^[13] However, US for intra-articular hip injections confers an advantage over the other imaging modalities in its ability to visualize neurovascular structures, assess muscular architecture, live monitoring of the needle, absence of radiation exposure for the patient and clinician, and convenience to the patient as an in-office procedure.^[6,8,14,15] The limitations of US include the training required to achieve proficiency and the financial burden of acquiring the necessary equipment. There is not any current research to suggest that an US-guided injection of the hip is more cost-effective for the patient, but typically in-office procedures require less cost than in a procedure suite where FL-guided injections are done. There is also existing research that suggests it is more cost effective for the patient with knee injections to complete their procedure in-office with US guidance than in a procedure suite.^[13]

The main limitation to this systematic review is the limited number of studies, the heterogeneity, and the outcomes measurement. Some articles focused on evaluating US versus

LM guidance, US versus FL guidance, and some on FL versus LM guidance. Studies included different inclusion/exclusion criteria, different skill levels of proceduralists, and evaluated different outcomes. This heterogeneity makes it more difficult to directly compare efficacy across the interventions. The sample sizes of the studies included were also relatively small. Future prospective, comparative studies comparing these different modalities for intra-articular hip injection are warranted.

In conclusion, this systematic review provides preliminary evidence for slightly better accuracy with US-guided intra-articular hip injections/arthrocentesis versus FL- or LM-guided intra-articular hip injections/aspirations. It contributes to the current literature by evaluating multiple measurable outcomes, including procedural accuracy, changes in pain scores, patient-reported procedural discomfort, and improvements in range of motion.

Declaration of Conflicting Interests

The authors declare that there are no conflicts of interest with respect to the research, authorship, and/or publication of this article.

Funding

This research received no specific grant from any funding agency in the public, commercial, or not-for-profit sectors.

Author Contributions

D.K., R.W., L.O., and N.J.: Conceptualized and designed the study; D.K., L.O., and N.J.: Developed the search strategy; D.K. and L.K.: Conducted the study selection and data extraction; A.H. and L.K.: Evaluated the risk of bias; A.H.: Performed the analysis and interpretation and wrote the initial draft of the manuscript; D.K.: Contributed to the writing and initial revisions of the manuscript; L.O. and N.J.: Completed the final review.

Data Availability

The datasets generated and/or analyzed during the current study are available from the corresponding author on reasonable request.

AI Disclosure

The authors declare that artificial intelligence (AI) tools were not used, or were used solely for language editing, and had no role in data analysis, interpretation, or the formulation of conclusions. All scientific content, data interpretation, and conclusions are the sole responsibility of the authors. The authors further confirm that AI tools

were not used to generate, fabricate, or 'hallucinate' references, and that all references have been carefully verified for accuracy.

REFERENCES

1. Heerey JJ, Kemp JL, Mosler AB, Jones DM, Pizzari T, Scholes MJ, et al. Correction to: What is the prevalence of hip intra-articular pathologies and osteoarthritis in active athletes with hip and groin pain compared with those without? A Systematic review and meta-analysis. *Sports Med* 2019;49:1139-41. doi: 10.1007/s40279-019-01108-7.
2. Hunt D, Prather H, Harris Hayes M, Clohisy JC. Clinical outcomes analysis of conservative and surgical treatment of patients with clinical indications of prearthritic, intra-articular hip disorders. *PM R* 2012;4:479-87. doi: 10.1016/j.pmrj.2012.03.012.
3. Hoeber S, Aly AR, Ashworth N, Rajasekaran S. Ultrasound-guided hip joint injections are more accurate than landmark-guided injections: A systematic review and meta-analysis. *Br J Sports Med* 2016;50:392-6. doi: 10.1136/bjsports-2014-094570.
4. Luchini C, Stubbs B, Solmi M, Veronese N. Assessing the quality of studies in meta-analyses: Advantages and limitations of the Newcastle Ottawa Scale. *World J Meta-Anal* 2017;5:80-4. doi: 10.13105/wjma.v5.i4.80.
5. Berona K, Abdi A, Menchine M, Mailhot T, Kang T, Seif D, et al. Success of ultrasound-guided versus landmark-guided arthrocentesis of hip, ankle, and wrist in a cadaver model. *Am J Emerg Med* 2017;35:240-4. doi: 10.1016/j.ajem.2016.10.056.
6. Byrd JW, Potts EA, Allison RK, Jones KS. Ultrasound-guided hip injections: A comparative study with fluoroscopy-guided injections. *Arthroscopy* 2014;30:42-6. doi: 10.1016/j.arthro.2013.09.083.
7. Furtado RN, Pereira DF, da Luz KR, dos Santos MF, Konai MS, Mitraud Sde A, et al. Effectiveness of imaging-guided intra-articular injection: a comparison study between fluoroscopy and ultrasound. *Rev Bras Reumatol* 2013;53:476-82. doi: 10.1016/j.rbr.2013.07.001.
8. Martínez-Martínez A, García-Espinosa J, Ruiz-Santiago F, Guzmán-Álvarez L, Castellano-García MM. Comparison of ultrasound and fluoroscopic guidance for injection in CT arthrography and MR arthrography of the hip. *Radiologia* 2016;58:454-9. doi: 10.1016/j.rx.2016.07.006.
9. Dıraçoğlu D, Alptekin K, Dikici F, Balci HI, Özçakar L, Aksoy C. Evaluation of needle positioning during blind intra-articular hip injections for osteoarthritis: Fluoroscopy versus arthrography. *Arch Phys Med Rehabil* 2009;90:2112-5. doi: 10.1016/j.apmr.2009.08.137.
10. Balog TP, Rhodehouse BB, Turner EK, Slevin JM, Bush LA, Grassbaugh JA, et al. Accuracy of ultrasound-guided intra-articular hip injections performed in the orthopedic clinic. *Orthopedics* 2017;40:96-100. doi: 10.3928/01477447-20161213-03.
11. Mei-Dan O, McConkey MO, Petersen B, McCarty E, Moreira B, Young DA. The anterior approach for a non-image-guided intra-articular hip injection. *Arthroscopy* 2013;29:1025-33. doi: 10.1016/j.arthro.2013.02.014.

12. Leopold SS, Battista V, Oliverio JA. Safety and efficacy of intraarticular hip injection using anatomic landmarks. *Clin Orthop Relat Res* 2001;(391):192-7. doi: 10.1097/00003086-200110000-00021.
13. Finnoff JT, Hall MM, Adams E, Berkoff D, Concoff AL, Dexter W, et al. American Medical Society for Sports Medicine (AMSSM) position statement: Interventional musculoskeletal ultrasound in sports medicine. *PM R* 2015;7:151-68.e12. doi: 10.1016/j.pmrj.2015.01.003.
14. Daniels EW, Cole D, Jacobs B, Phillips SF. Existing evidence on ultrasound-guided injections in sports medicine. *Orthop J Sports Med* 2018;6:2325967118756576. doi: 10.1177/2325967118756576.
15. Chiamonte R, Bonfiglio M, Castorina EG, Antoci SAM. The primacy of ultrasound in the assessment of muscle architecture: Precision, accuracy, reliability of ultrasonography. *Physiatrist, radiologist, general internist, and family practitioner's experiences. Rev Assoc Med Bras (1992)* 2019;65:165-70. doi: 10.1590/1806-9282.65.2.165.